

# Would Self-Expanding Stent Occlude Middle Cerebral Artery Perforators?

Thomas W. Leung, MRCP; Simon C.H. Yu, FRCR; Wynn W.M. Lam, FRCR;  
Anne Y.Y. Chan, MRCP; Alexander Y.L. Lau, MRCP; Lawrence K.S. Wong, MD

**Background and Purpose**—A major concern of intracranial stenting is perforator infarction. It is unclear whether the sustained radial force of a self-expanding stent or subsequent stent restenosis would cause late occlusion of perforators.

**Methods**—We compared the baseline and poststent ( $\geq 4$  months) MRI scans of patients who underwent self-expanding stenting for recurrent ischemic symptoms attributed to a MCA stenosis  $\geq 60\%$ . New infarcts in the ipsilateral striatocapsular region were recorded.

**Results**—MCA stenting was technically successful in 23 of 24 recruited patients. No new perforator territory infarct was found in follow-up MRI scans of all recruited patients. Postoperatively, all patients reported no further TIA or stroke over a median follow-up of 15 months.

**Conclusions**—The use of a self-expanding stent in patients with high-grade MCA stenosis may not pose a major risk to the perforators. (*Stroke*. 2009;40:1910-1912.)

**Key Words:** intracranial stenosis ■ angioplasty ■ stenting ■ perforator territory infarction

One fourth of patients with high grade symptomatic intracranial stenosis may develop recurrent ipsilateral stroke within 2 years.<sup>1</sup> The lack of successful medical treatment prompted stenting as adjunctive therapy.<sup>2</sup>

One major concern of intracranial stenting is perforator occlusion from “snow plowing” effect (ie, forceful displacement of atheroma into the perforator ostia), attributed to high deployment pressure of balloon-mounted stent.<sup>3</sup> The Wingspan stent system (Boston Scientific) adopted submaximal dilatation, in which balloon predilatation was  $\leq 80\%$  of the adjacent normal vessel diameter. The self-expanding stent then might further expand to its predetermined size through a sustained radial force on the vessel wall. However, it is uncertain whether this progressive stent expansion would subacutely displace the plaque fractured in predilatation, causing late perforator occlusion. Besides, the high frequency of stent restenosis in the Wingspan registry raises a safety concern on the perforators within the restenotic segment as they may be susceptible to occlusion by neointimal hyperplasia.<sup>2,4</sup>

We prospectively investigated whether late perforator infarction (PI) would develop after MCA angioplasty with Wingspan.

## Materials and Methods

The study was approved by the Institutional Review Board. Patients with acute stroke or TIA attributed to high-grade MCA stenoses ( $>60\%$ ) were recruited for MCA stenting between February 2006

and January 2008. Exclusion criteria included: (1) stroke etiology incompatible with intracranial atherosclerotic disease; (2) NIH stroke Scale  $>8$ ; and (3) contraindications to dual antiplatelets and heparin.

## MRI Examination

Cranial MRI scans were performed with a 1.5T scanner (Sonata, Siemens Medical). Each MRI examination comprised axial images of diffusion weighted imaging (TR/TE:3400/122 ms, excitation=4, matrix=128 $\times$ 128, field of view [FOV]=230 mm, slice thickness/gap=5/1 mm, matrix=128 $\times$ 128, EPI factor=90, with three orthogonally applied gradients, with b values of 0, 500, and 1000), T1-weighted (TR/TE=425/14 ms, excitation=2, FOV=230 mm, slice thickness/gap=5/0.5 mm, matrix=256 $\times$ 256), T2-weighted (TR/TE=2500/120 ms, excitation=1, turbo factor=15, FOV=230 mm, slice thickness/gap=5/0.5 mm, matrix=256 $\times$ 256), and fluid attenuated inversion recovery (FLAIR) sequences (TR/TE/TI=9000/117/2500 ms, excitation=2, slice thickness/gap=5/1 mm, matrix=256 $\times$ 256).

## Interventional Procedure and Follow-Up

Aspirin 80 mg daily and clopidogrel 75 mg daily were begun 3 days before the procedure. Under regional anesthesia and anticoagulation, the MCA lesion was first crossed by an exchange length floppy tip 0.014-inch microwire, and then dilated up to 80% of the normal adjacent segment by a Gateway balloon. The stenosis was then straddled by a Wingspan stent which was sized to be equal to or the next size up from the largest vessel diameter.

Postoperatively, dual antiplatelet therapy was continued for 6 weeks, followed by aspirin for life. Clinical follow-up was scheduled on day-30, 3 months, and 6 months. Follow-up MRI was performed in 4 months.

An independent neuroradiologist compared the baseline and follow-up MRI scans. Any new infarct in the ipsilateral striatocapsular region was recorded.

Received July 23, 2008; accepted August 28, 2008.

From the Division of Neurology, Department of Medicine and Therapeutics (T.W.L., A.Y.Y.C., A.Y.L.L., L.K.S.W.), and the Department of Radiology and Organ Imaging (S.C.H.Y., W.W.M.L.), Prince of Wales Hospital, The Chinese University of Hong Kong.

Correspondence to Thomas W. Leung, Division of Neurology, Department of Medicine and Therapeutics, Prince of Wales Hospital, The Chinese University of Hong Kong. E-mail: drtleung@cuhk.edu.hk

© 2009 American Heart Association, Inc.

Stroke is available at <http://stroke.ahajournals.org>

DOI: 10.1161/STROKEAHA.108.532416

**Table. Demographics, Treatment Results, and MRI Findings of the Patients**

No.	Sex/Age	Stenosis: Site/Degree	Baseline Ipsilateral Perforator Territory Infarct	Prestent Infarct Topography	Stent Size: Diameter/Length (mm)	Immediate Poststent Stenosis
1	M/75	LM1/60%; LC7/77%	+	Bilateral internal borderzone (BZ) and lentiform nuclei (LN)	3.5/20	LM1/10%; LC7/20%
2	M/74	RM1/60%;  RC7/83%	—	Right corona radiata (CR) and internal BZ	4.5/20	RM1/10%;  RC7/25%
3	M/46	LM1/74%	—	No infarct	3.0/9.0	10%
4	M/67	RM1/82%	+	Right anterior BZ and bilateral LN	3.5/20	15%
5	M/79	LM1/63%	+	Bilateral partial internal BZ, right LN and left caudate nucleus	3.5/20	20%
6	M/55	LM1/62%	—	Left temporo-parietal lobe	3.0/15	30%
7	M/54	LM1/74%	—	Left partial internal BZ, right LN and right cerebellum	2.5/15	40%
8	M/79	RM1/72%	—	Right anterior BZ	2.5/9.0	25%
9	M/34	LM1/70%	—	Left CR	2.5/9.0	19%
10	M/64	LM1/78%	+	Left LN and right CR	3.5/15	35%
11	M/70	RM1/91%	+	Right CR, right fronto-parietal lobe and left LN	3.0/15	32%
12	F/74	RM1/74%	—	Right CR	2.5/9.0	19%
13	M/69	RM1/60%	+	Bilateral CR and right LN	3.0/9.0	10%
14	F/71	LM1/62%	+	Left head of caudate nucleus and LN	2.0/9.0	30%
15	F/67	LM1/78%; LM2/84%	+	Left LN	2.5/15	LM1/40%; LM2/40%
16	M/54	RM1 61%	—	Right fronto-parietal and CR	3.5/20	10%
17	M/50	LM1/83%	—	Left CR	3.0/15	10%
18	M/54	LM1/83%	—	No infarct	*2.5/9.0 2.5/15	20%
19	M/51	LM1/73%	—	No infarct	3.0/20	10%
20	M/59	RM1/60%	+	Right thalamo-capsular and left LN	2.5/9.0	10%
21	F/49	RM1/75%;  RC7/70%	+	Right parieto-temporal and striato-capsular infarcts	3.0/20	RM1/20%;  RC7/20%
22	M/71	LM1/74%	+	Left parietal and LN	2.5/15	35%
23	M/73	LM1 80%	+	Left LN	Procedure abandoned due to TIA	—
24	F/63	LM1 96%	+	Left LN and CR	2.5/15	20%

+ indicates present; —, absent; R, right; L, left; M1/M2, M1/M2 segment of middle cerebral artery; C7, communicating segment of internal carotid artery; BZ, borderzone; CR, corona radiata; LN, lentiform nucleus; \*two stents were needed to bridge the disease segment.

## Results

Twenty-four patients were recruited. The Table summarized the demographics, MRI findings, and angioplasty results. Nineteen patients were men. Median age was 65.5 years (interquartile range [IQR] 54 to 72 years). Twenty-one patients had recurrent strokes, and 3 had refractory TIAs despite medical treatment.

The procedure was prematurely terminated in one patient when he developed transient hemiparesis during passage of the balloon catheter across the target lesion.

In the remaining 23 patients, balloon dilatation and stenting were technically successful. The median stenosis reduced from 74% (IQR, 62% to 82%) prestent to 20% (IQR, 10% to 30%) immediate poststent. In 4 patients who had tandem stenoses at C7 segment of internal carotid artery (n=3) or M2

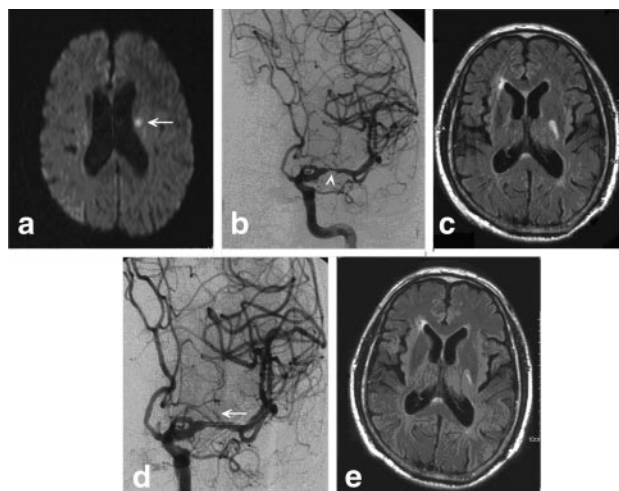
segment of MCA (n=1), the tandem stenoses were treated concurrently with the MCA lesion by a single stent.

Postoperatively, all recruited patients reported no further TIA or stroke over a median follow-up of 15 months. No new PI was found in follow-up MRI scans of all 24 patients (Figure).

## Discussion

Our finding suggests that self-expanding stenting for high-grade MCA stenosis may not pose a major risk to the perforators.

The surveillance of PI in our study was reinforced by MRI and its uniform acquisition in all patients. Moreover, the follow-up imaging was scheduled beyond the peak of neointimal hyperplasia so as to reflect the potential adverse effect



**Figure.** Case 10: MR diffusion-weighted imaging showed acute left corona radiata infarct (a), attributed to the left MCA stenosis (b). Left lentiform nucleus infarct was revealed at baseline FLAIR imaging (c). Poststent lenticulostriate arteries remained patent (d, arrow). Follow-up MRI showed no new infarct in the corresponding striato-capsular region (e).

of neointimal proliferation over the perforator ostia. Yet, all patients had no new PI.

As an open-cell stent, Wingspan conforms better than a close-cell stent to the curved anatomy of MCA. Wingspan also exerts far less radial pressure to the vessel wall (25 mm Hg at nominal diameter), comparing to the 6 to 8 atmospheric pressures in deployment of balloon-mounted stent. These properties of Wingspan may contribute to less vascular trauma and plaque disruption.

However, when balloon-mounted stents were the only option for intracranial stenting, “staged approach” (ie, submaximal balloon dilatation followed by stenting in 6 weeks) was shown to reduce periprocedural stroke risk.<sup>5</sup> It was suggested that intimal fibrosis and vascular remodeling fostered in the interim period might reduce “snow plowing effect” in subsequent stenting.<sup>6</sup> The Wingspan system adopts submaximal dilatation, yet the staged procedures are combined. Lacking an interim period for intimal fibrosis and remodeling, the expanding stent may still displace the newly fractured plaque and occlude the perforator ostia.

Furthermore, in the U.S. Wingspan registry, 29 of 78 patients (37%) developed stent restenosis or thrombosis over a mean follow-up of 6 months.<sup>2,4</sup> Although stenting prevents initial elastic recoil, metal stent triggers neointimal proliferation, proportional to the degree of penetration of the vessel

wall by stent struts.<sup>7</sup> It is uncertain whether the sustained radial force of Wingspan may aggravate neointimal hyperplasia. In coronary vasculature, neointimal hyperplasia causes stent restenosis, branch occlusion, and symptom recurrence.<sup>8</sup> Similarly, neointimal proliferation in cerebral vessels may occlude perforators, causing infarction where collateral is minimal.

The effects of self-expanding stent on the cerebral vascular milieu remain unclear. Study on long-term outcome of intracranial stenting is warranted. Limitations to our study include: First, the poststent effect on M2 perforators could not be assessed as stenting was mostly performed within M1 segment; Second, small PI might have escaped detection given the thickness of the slice in MRI scans.

## Sources of Funding

This study is funded by SH Ho Foundation, Vascular and Interventional Radiology Foundation, and Department of Medicine and Therapeutics, The Chinese University of Hong Kong.

## Disclosures

None.

## References

1. Kasner SE, Chimowitz MI, Lynn MJ, Howlett-Smith H, Stern BJ, Hertzberg VS, Frankel MR, Levine SR, Chaturvedi S, Benesch CG, Sila CA, Jovin TG, Romano JG, Cloft HJ; Warfarin Aspirin Symptomatic Intracranial Disease Trial Investigators. Predictors of ischemic stroke in the territory of a symptomatic intracranial arterial stenosis. *Circulation*. 2006; 113:555–563.
2. Zaidat OO, Klucznik R, Alexander MJ, Chaloupka J, Lutsep H, Barnwell S, Mawad M, Lane B, Lynn MJ, Chimowitz M; NIH Multi-center Wingspan Intracranial Stent Registry Study Group. The NIH registry on use of the Wingspan stent for symptomatic 70–99% intracranial arterial stenosis. *Neurology*. 2008;70:1518–1524.
3. Levy EI, Chaturvedi S. Perforator stroke following intracranial stenting: A sacrifice for the greater good? *Neurology*. 2006;66:1803–1804.
4. Levy EI, Turk AS, Albuquerque FC, Niemann DB, Aagaard-Kienitz B, Pride L, Purdy P, Welch B, Woo H, Rasmussen PA, Hopkins LN, Masaryk TJ, McDougall CG, Fiorella DJ. Wingspan in-stent restenosis and thrombosis: incidence, clinical presentation, and management. *Neurosurgery*. 2007;61:644–651.
5. Levy EI, Hanel RA, Bendok BR, Boulos AS, Hartney ML, Guterman LR, Qureshi AI, Hopkins LN. Staged stent-assisted angioplasty for symptomatic intracranial verteobasilar artery stenosis. *J Neurosurg*. 2002;97: 1294–1301.
6. Tanaka H, Sukhova GK, Swanson SJ, Clinton SK, Ganz P, Cybulsky MI, Libby P. Sustained activation of vascular cells and leukocytes in the rabbit aorta after balloon injury. *Circulation*. 1993;88:1788–1803.
7. Farb A, Weber DK, Kolodgie FD, Burke AP, Virmani R. Morphological predictors of restenosis after coronary stenting in humans. *Circulation*. 2002;105:2974–2980.
8. Aliabadi D, Tilli FV, Bowers TR, Benzuly KH, Safian RD, Goldstein JA, Grines CL, O'Neill WW. Incidence and angiographic predictors of side branch occlusion following high-pressure intracoronary stenting. *Am J Cardiol*. 1997;80:994–997.

## Would Self-Expanding Stent Occlude Middle Cerebral Artery Perforators?

Thomas W. Leung, Simon C.H. Yu, Wynn W.M. Lam, Anne Y.Y. Chan, Alexander Y.L. Lau and Lawrence K.S. Wong

*Stroke*. 2009;40:1910-1912; originally published online January 29, 2009;  
doi: 10.1161/STROKEAHA.108.532416  
*Stroke* is published by the American Heart Association, 7272 Greenville Avenue, Dallas, TX 75231  
Copyright © 2009 American Heart Association, Inc. All rights reserved.  
Print ISSN: 0039-2499. Online ISSN: 1524-4628

The online version of this article, along with updated information and services, is located on the World Wide Web at:

<http://stroke.ahajournals.org/content/40/5/1910>

**Permissions:** Requests for permissions to reproduce figures, tables, or portions of articles originally published in *Stroke* can be obtained via RightsLink, a service of the Copyright Clearance Center, not the Editorial Office. Once the online version of the published article for which permission is being requested is located, click Request Permissions in the middle column of the Web page under Services. Further information about this process is available in the [Permissions and Rights Question and Answer](#) document.

**Reprints:** Information about reprints can be found online at:  
<http://www.lww.com/reprints>

**Subscriptions:** Information about subscribing to *Stroke* is online at:  
<http://stroke.ahajournals.org/subscriptions/>